

Providence St. Joseph Health

Providence St. Joseph Health Digital Commons

Providence Portland Medical Center Internal
Medicine 2021

Providence Portland Medical Center Internal
Medicine

5-2021

Double the Battle: Two Cases of Irreversible Endocrinopathies in Patients Already Fighting Metastatic Cancer.

Olesya Petrenko

Nicholas L Stucky

Follow this and additional works at: https://digitalcommons.psjhealth.org/oaa_ppmc_21



Part of the [Internal Medicine Commons](#), and the [Oncology Commons](#)

Double the Battle: Two Cases of Irreversible Endocrinopathies in Patients Already Fighting Metastatic Cancer.

Olesya Petrenko D.O. & Nicholas L. Stucky M.D
No Disclosures

INTRODUCTION: Emergence of cancer immunotherapy has instigated a new era in field of oncology and revolutionized treatment of cancer. In **2011**, Immune Checkpoint Inhibitors (ICI) gained approval for treatment of advanced solid and hematological malignancies and have had remarkable results. Since being released, new cases of irreversible endocrine adverse events are increasingly becoming reported and leave patients with a new life-long diagnosis after battling metastatic cancer.

We present two cases of rare endocrinopathies after the use of ICIs.

Case #1

- 47 year old male with metastatic melanoma → 5 days of nausea, vomiting, polyuria, polydipsia
- No prior medical history of diabetes mellitus
 - Melanoma of his lower back with inguinal lymph node metastases
 - Wide margin + sentinel lymph node excision
 - 3 years later → CT Chest Abdomen Pelvis: metastatic pulmonary nodules, bladder wall nodule
 - PET CT: lung nodules, mediastinal lymphadenopathy, gallbladder nodule, low back soft tissue mass, bladder lesion (extensive metastatic disease)
 - Started on **Nivolumab** and **Ipilimumab**

Vital Signs and Physical Exam:

- Afebrile, pulse 114, BP 136/84, RR 22, SpO2 100% RA
- General: Pleasant adult male, well-nourished, tachypneic and fatigued appearing.
- Abdomen: Soft, nontender, no palpable masses.

Lab Results

Lab value	Result
White Blood Cell Count	19.7 (84% PMNs)
Sodium	129
Potassium	6.2
Bicarbonate	6
Creatinine	2.43 (baseline 1.1)
Glucose	676
Anion Gap	26
Beta-hydroxybutyrate	11.7
Hemoglobin A1c	7.1%
C-peptide	<1
AM Cortisol	56
TSH, free T4	0.08, 1.47

Hospital Course

- Diagnosed with DKA → aggressive fluids, insulin drip. No underlying infection.
- Pseudo-hyponatremia in the setting of hyperglycemia
- New prerenal AKI (dehydration) → hyperkalemia
- Adrenal insufficiency work up negative
 - No stress dose steroids.
- Undetected C-peptide → **new onset type I diabetes mellitus in the setting of nivolumab and ipilimumab use.**
- Started on an insulin regimen outpatient

Case #2

- 81 year-old female with metastatic bladder cancer → 2 weeks of fatigue, positional dizziness, dyspnea
- Denied fever, chills, dysuria, abdominal pain
 - Admitted 2 weeks prior with acute hyperkalemia from dehydration, poor appetite.
 - Bladder cancer 5 years ago, underwent TURB x3
 - 4 years later → mediastinal metastases
 - Started on Cisplatin and Gemcitabine
 - Due to progression of her cancer → switched to **Pembrolizumab (Keytruda)**

Vital Signs and Physical Exam:

- Afebrile, pulse 90, BP 81/59, RR 16, SpO2 97% on RA
- General: Pleasant, thin female, mildly dyspneic in the room. Dry mucous membranes.
- Cardiac: Low JVP
- Skin: No hyperpigmentation noted

Lab Results

Lab value	Result
White blood cell count	8.8
Sodium	131
Potassium	4.0
D-dimer	1.99
Troponin	0.1 → 0.09
Lactic Acid	1.3
Procalcitonin	0.09
AM Cortisol	<1
ACTH	458
Cosyntropin stimulation test	Cortisol <1

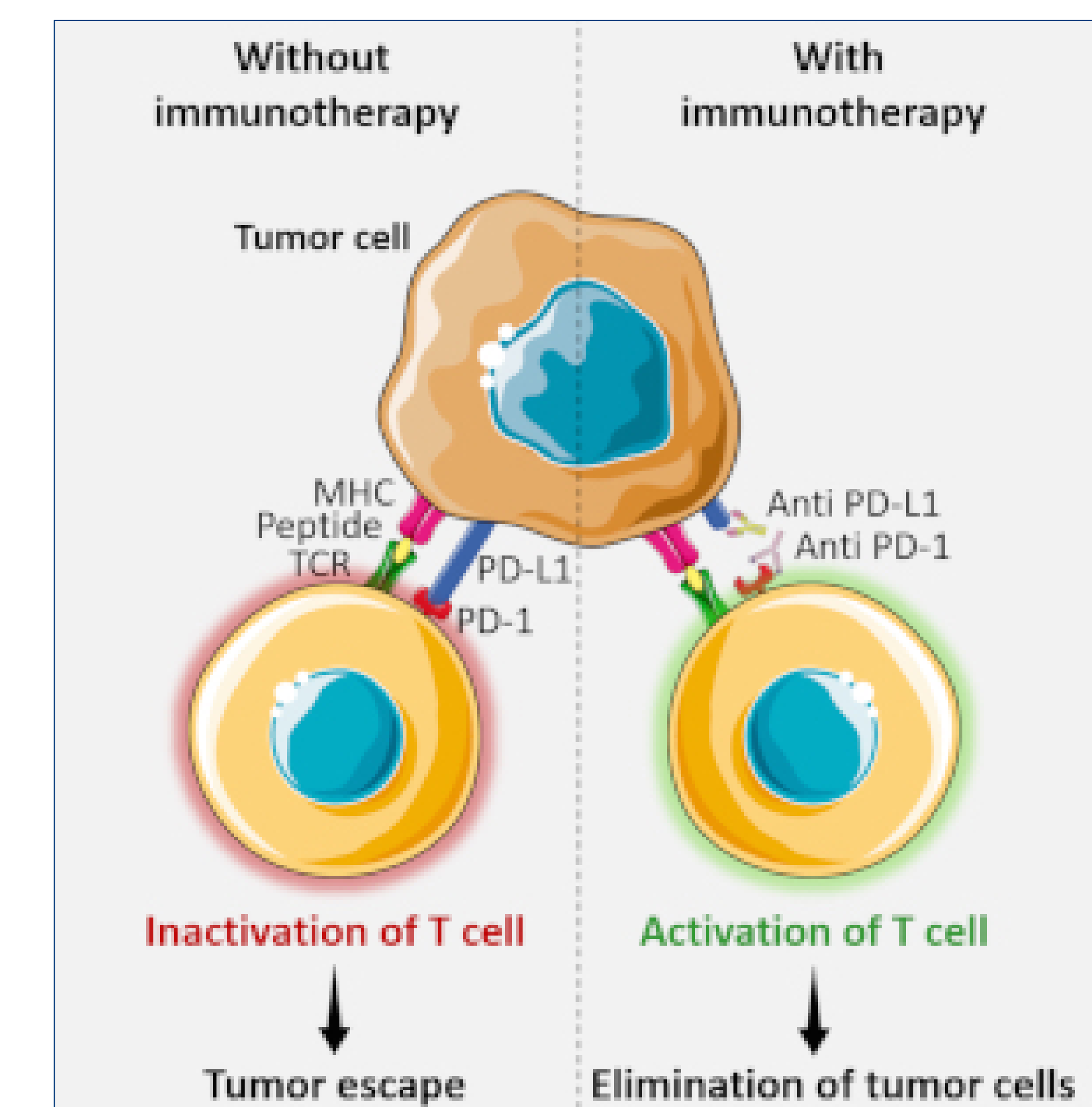
- CTA Chest:** No consolidation, pulmonary embolus. Enlarged mediastinal lymph nodes.
- CT Abdomen-Pelvis W Contrast:** Unremarkable
- Urinary Analysis (UA):** 2+ Leukocyte esterase, 25-50 WBC, 1+ bacteria

Hospital Course

- Started on empiric antibiotics for urosepsis
- Persistent hypotension → further work up for adrenal insufficiency
 - Undetected morning cortisol + elevated ACTH → Primary Adrenal Insufficiency due to Keytruda
- 21-hydroxylase enzymes not checked
- Started on hydrocortisone
- On outpatient follow up → persistent dizziness, hyperkalemia, fludrocortisone added.

Discussion

- 6 Immune Checkpoint Inhibitors (ICIs) approved:**
 - CTLA-4 (cytotoxic T-lymphocyte-associated protein 4) inhibitor **Ipilimumab**
 - PD-1 (programmed cell death protein 1) inhibitors **nivolumab, pembrolizumab**
 - PD-L1 (programmed cell death ligand 1) inhibitors **atezolizumab, avelumab, durvalumab**
- T-cell surface receptors → immunological tolerance to self-antigens, prevent autoimmune disorders
- Endocrine dysfunction – most common adverse effect
 - Hypothyroidism, hyperthyroidism, hypophysitis, primary adrenal insufficiency, insulin-deficient diabetes
- Higher with combination therapy
- Thyroid dysfunction most common
 - Life-threatening thyroid storm: anti-PD1 agents
 - Destructive thyroiditis by cytotoxic cells against thyroid gland (thyroid gland expresses both PD-L1, PD-L2 molecules)
- Hypophysitis most common with ipilimumab (CTLA-4 protein expressed in pituitary glands)
- Primary adrenal insufficiency – very rare (0.7%)
- Insulin-dependent diabetes: with anti-PD1 therapy and Ipilimumab
- Current guidelines recommend baseline screening with TFTs, morning cortisol and ACTH and screening monthly thereafter.



References

Byun, D.J., Wolchok, J.D., Rosenberg, L.M., & Girotra, M. (2017) *Cancer Immunotherapy – immune checkpoint blockade and associated endocrinopathies*. Nature Reviews Endocrinology. 13:195-207

Girotra, M., Hansen, A., Farooki, A., Byun, D.J., Min, L., Creelan, B.C., Callagan, M.K., Atkins, M.B., Sharon, E., Antonia, S.J., West, P., Gravell, A.E. (2018) *The Current Understanding of the Endocrine effects from Immune Checkpoint Inhibitors and Recommendations for Management*. JNCI Cancer Spectrum 2(3).

Zhai, Y., Ye, X., Hu, F., Xu, J., Guo, X., Zhuang, Y., & He, J. (2019) *Endocrine toxicity of immune checkpoint inhibitors: a real-world study leveraging US Food and Drug Administration adverse events reporting system*. Journal for ImmunoTherapy of Cancer. 7(286).