

Providence St. Joseph Health

## Providence St. Joseph Health Digital Commons

---

Providence St. Vincent Internal Medicine

Oregon Academic Achievement

---

4-29-2020

### Struck By Lightning Twice

Bao-Ngoc Nguyen

*Providence St. Vincent, Internal Medicine Residency, Portland, Oregon, Bao-Ngoc.Nguyen@providence.org*

Emily Hitchcock

*Providence St. Vincent, Internal Medicine, Portland, Oregon, Emily.Hitchcock@providence.org*

Follow this and additional works at: [https://digitalcommons.psjhealth.org/psv\\_internal](https://digitalcommons.psjhealth.org/psv_internal)



Part of the [Internal Medicine Commons](#)

---

#### Recommended Citation

Nguyen, Bao-Ngoc and Hitchcock, Emily, "Struck By Lightning Twice" (2020). *Providence St. Vincent Internal Medicine*. 12.

[https://digitalcommons.psjhealth.org/psv\\_internal/12](https://digitalcommons.psjhealth.org/psv_internal/12)

This Poster is brought to you for free and open access by the Oregon Academic Achievement at Providence St. Joseph Health Digital Commons. It has been accepted for inclusion in Providence St. Vincent Internal Medicine by an authorized administrator of Providence St. Joseph Health Digital Commons. For more information, please contact [digitalcommons@providence.org](mailto:digitalcommons@providence.org).



# Struck By Lightning Twice

Bao-Ngoc Nguyen, MD and Emily Hitchcock, MD

Providence St. Vincent, Internal Medicine Residency, Portland, Oregon

## INTRODUCTION

ANCA-associated vasculitides (AAV) refer to a group of disorders causing inflammation of small vessels which include granulomatosis with polyangiitis (GPA), microscopic polyangiitis (MPA), and eosinophilic granulomatosis with polyangiitis (EGPA, Churg-Strauss). Here I present a case of MPA vasculitis in a patient with alpha-1-antitrypsin (AAT) deficiency, and describe a proposed causal link between these two rare disease processes.

## CASE REPORT

- 43-year-old man with history of newly-diagnosed AAT deficiency liver disease.
- Chief complaint of subacute shortness of breath associated with hemoptysis and fever for 5 months.
- Symptoms had been progressively worsening despite multiple courses of antibiotics and inhalers.
- Pulmonary CT angiogram (CTPA) was negative for pulmonary embolism but showed “multifocal pulmonary infiltrates for which pneumonia and septic emboli could not be excluded”.
- Infectious workup negative.
- Positive myeloperoxidase (MPO) antibodies and findings on thoroscopic lung biopsy most consistent with MPA.
- Managed with steroids and rituximab.

## FIGURES

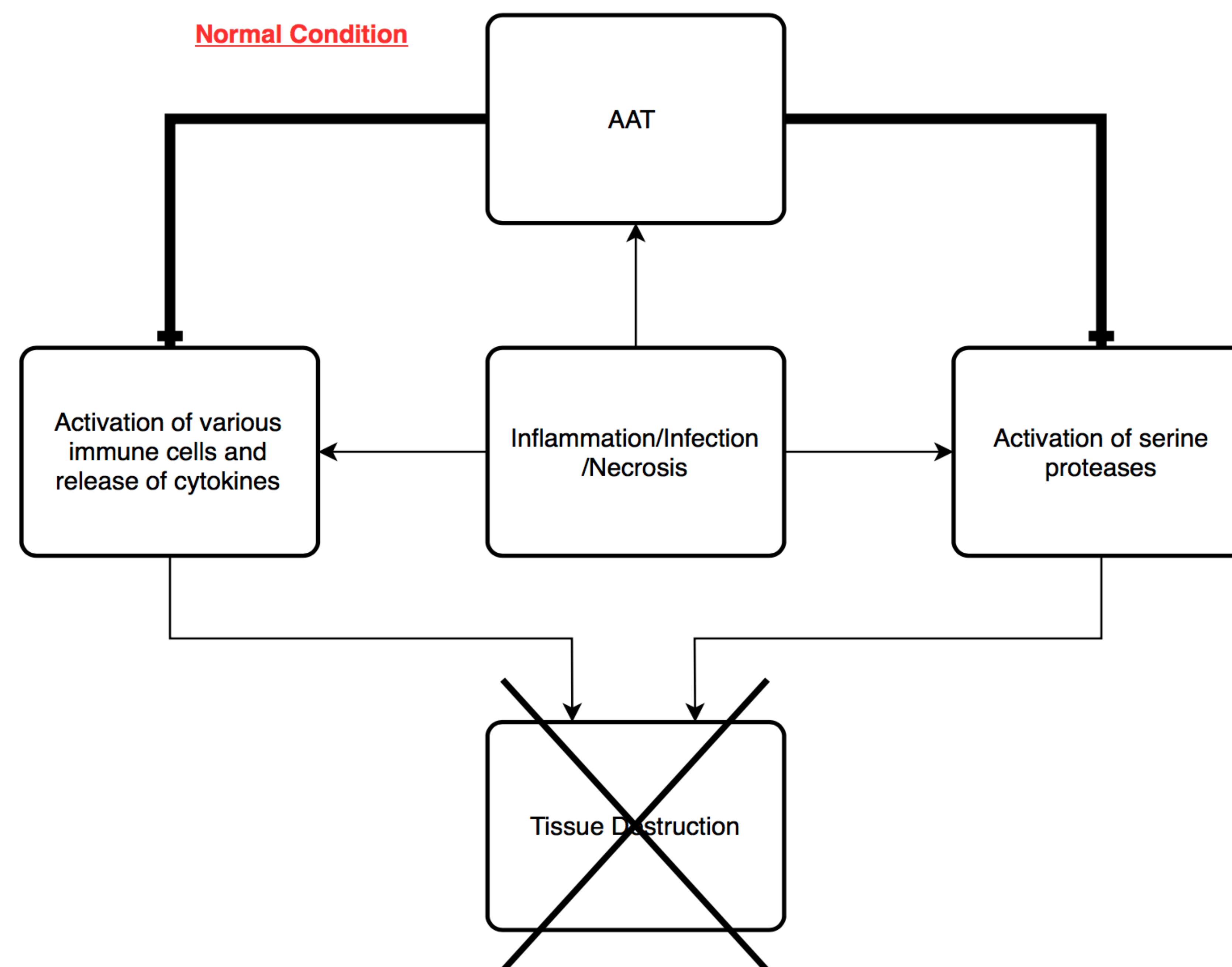


Figure 2. Mechanism of action of AAT

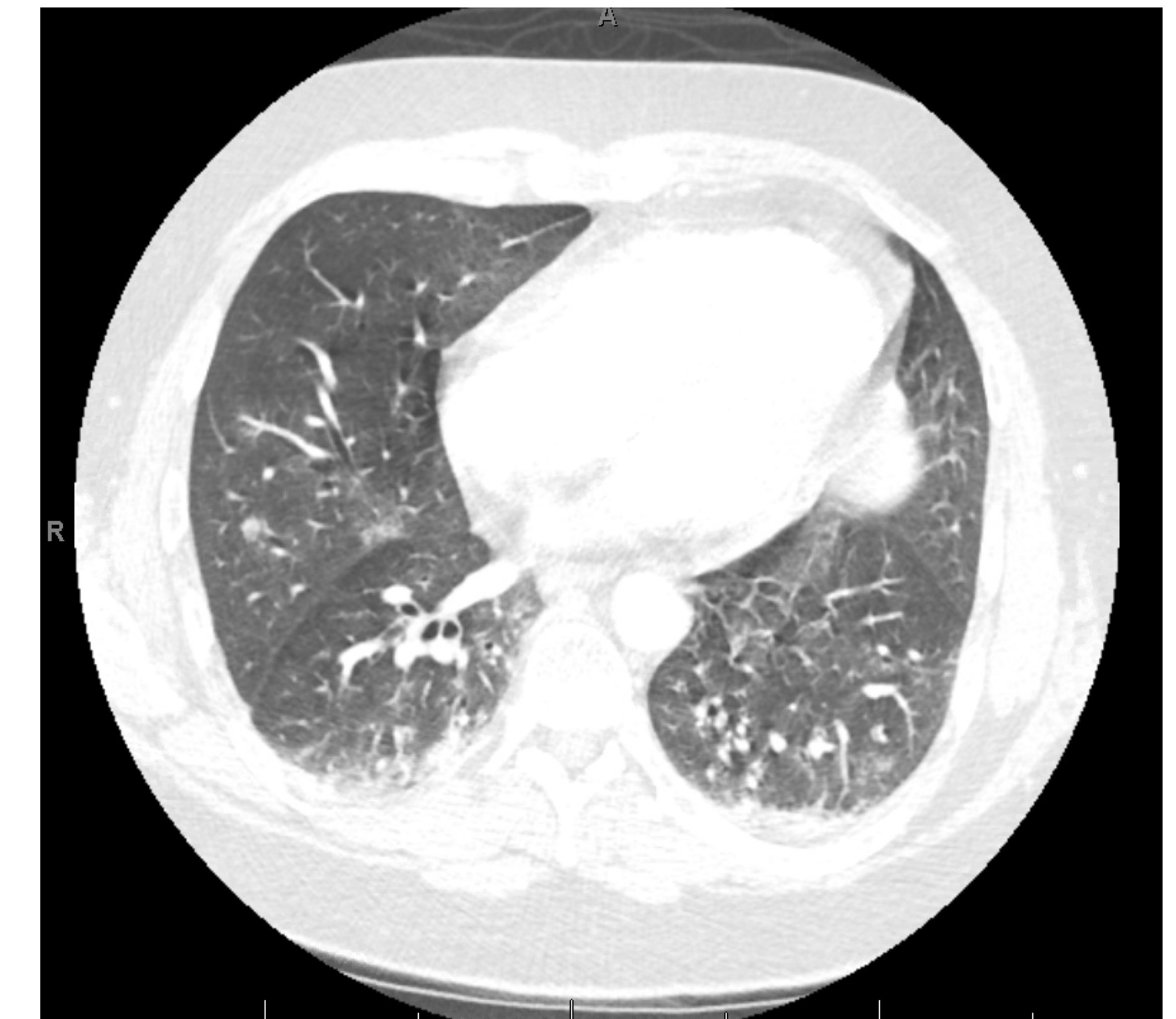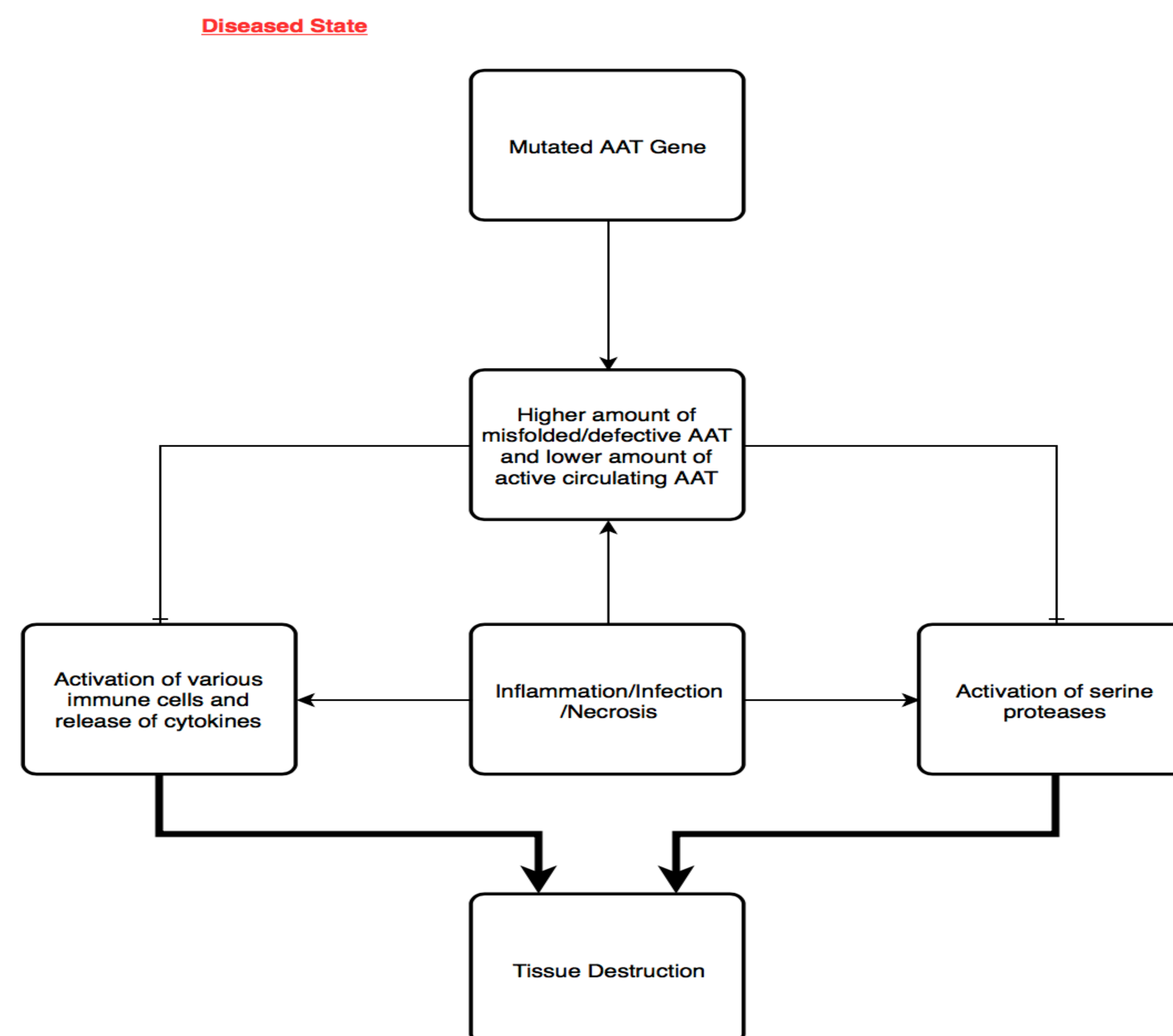


Figure 1. Bibasilar subsegmental dependent densities, scattered groundglass and alveolar nodular/interstitial densities bilaterally, several collapsed or opacified lower lobe bronchi

## DISCUSSION

- AAT is an acute-phase protein that inhibits the serine proteases of inflammatory cells, including proteinase 3 (PR3), to protect tissues from damage.
- Mutations in the AAT-encoding gene SERPINA1 result in a structural change in AAT that inhibits its release into the bloodstream, leading to higher levels of proteases in the blood that can then cause excessive tissue damage.
- Because increased levels of PR3 is a major component in the pathogenesis of ANCA vasculitis, a causal link between AAT deficiency and ANCA vasculitis has been proposed. There are many case reports describing this association, but the level of detail is variable based on the tests available at the time of the report.
- Even though ANCA vasculitis is relatively rare, it is worth considering and pushed closer to the top of the differential list when a concurrent history of AAT deficiency is present.